

GUT – C
04/11/2019

Gagandeep Kaur, M.D.

PGY 1

Danbury hospital

CLINICAL HISTORY

03/28/2018

26 years old female with no significant past medical history.

Presented with bilateral pleuritic chest pain and progressive shortness of breath.

Elevated D- Dimer.

Has history of Bird exposure.

CXR showed left lung masses (up to 3.3 cm) and right mid lung nodular opacity, nonspecific.

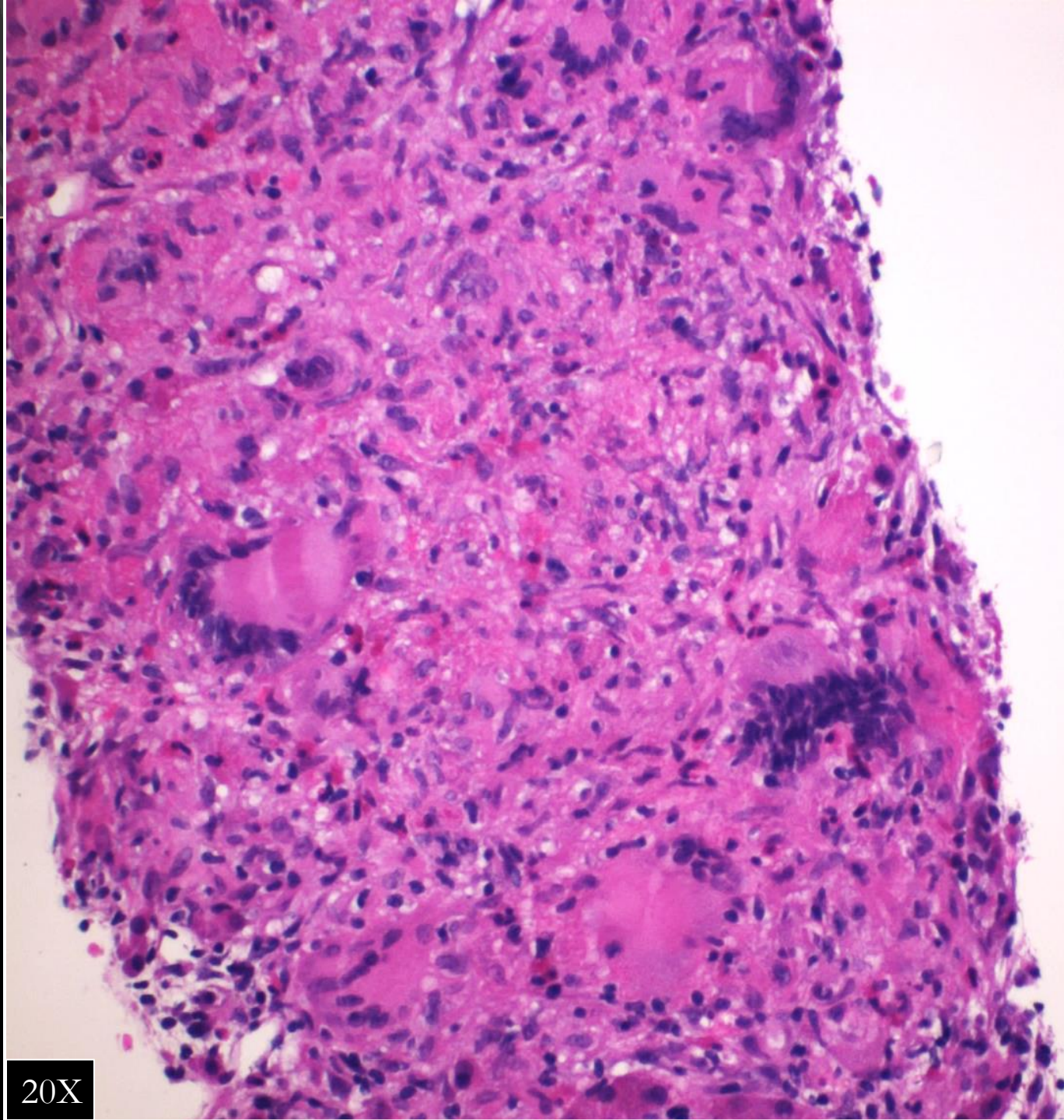
On 04/02/2018, PET scan shows activity in multiple liver lesions and multiple bilateral lung nodules.

LIVER, CT-GUIDED
CORE NEEDLE BIOPSY,
04/06/2018

10X



LIVER, CT-
GUIDED CORE
NEEDLE BIOPSY,
04/06/2018



20X



THANK YOU