

GUT-C

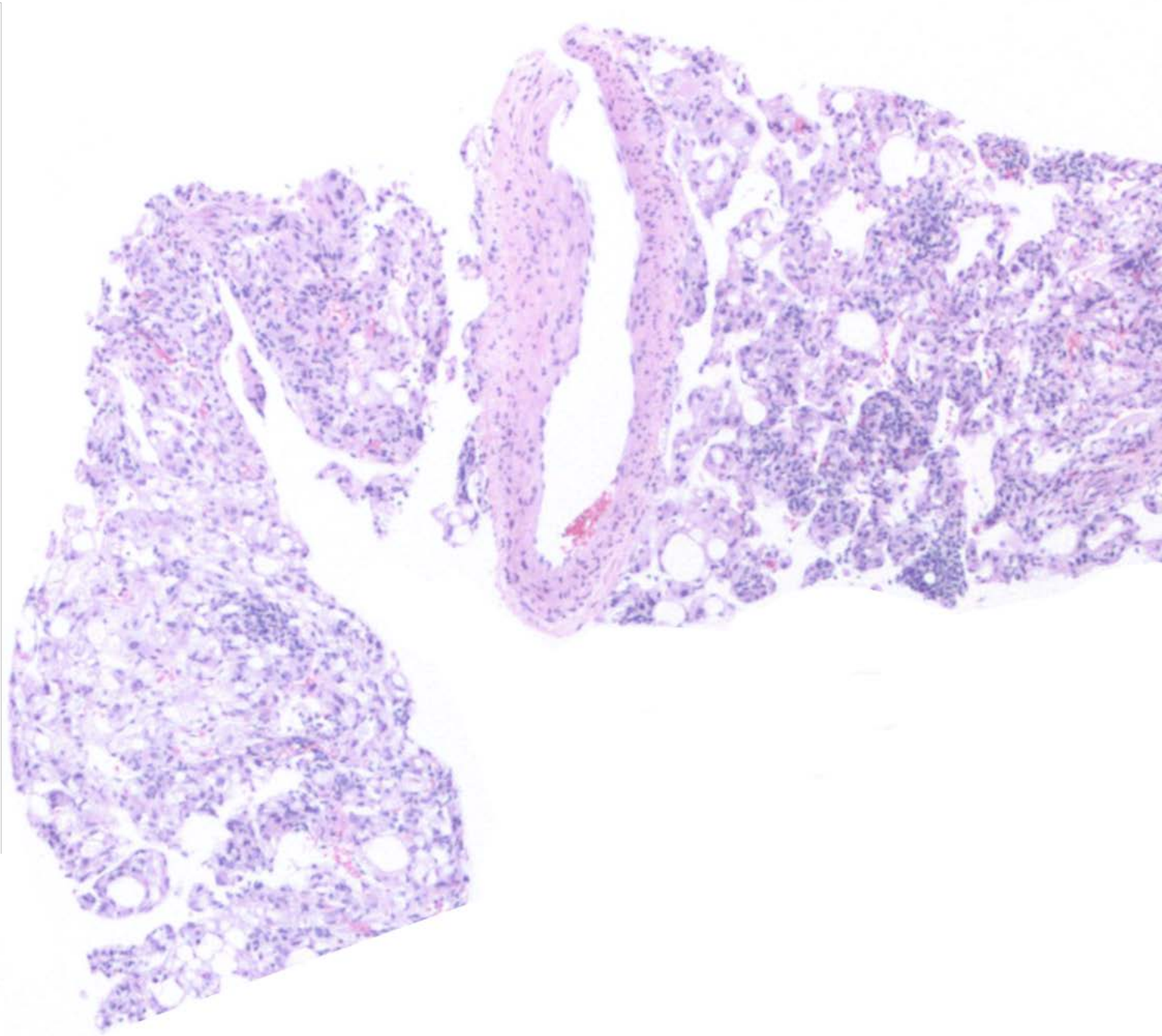
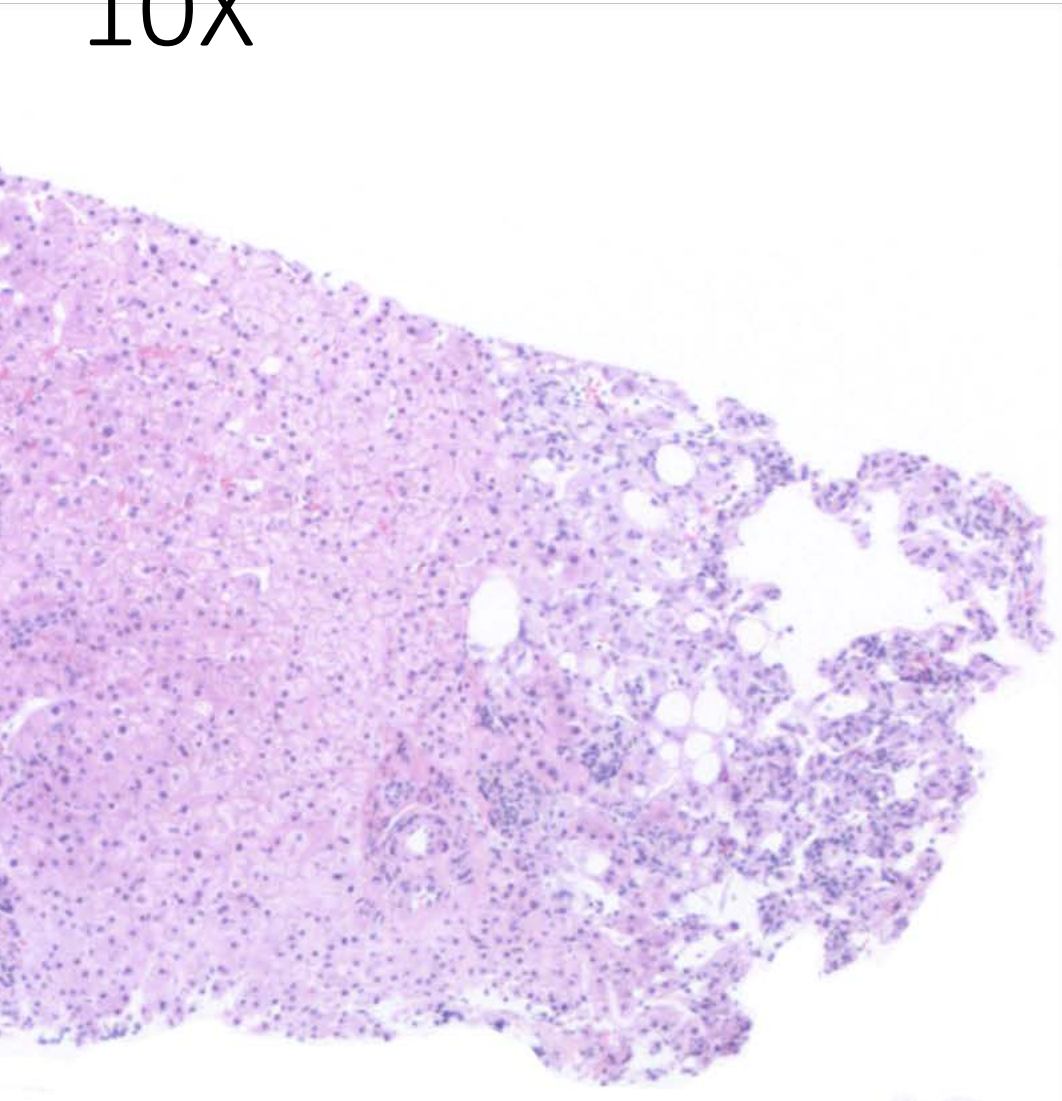
Austin McHenry, MD

PGY1, Yale New Haven Hospital

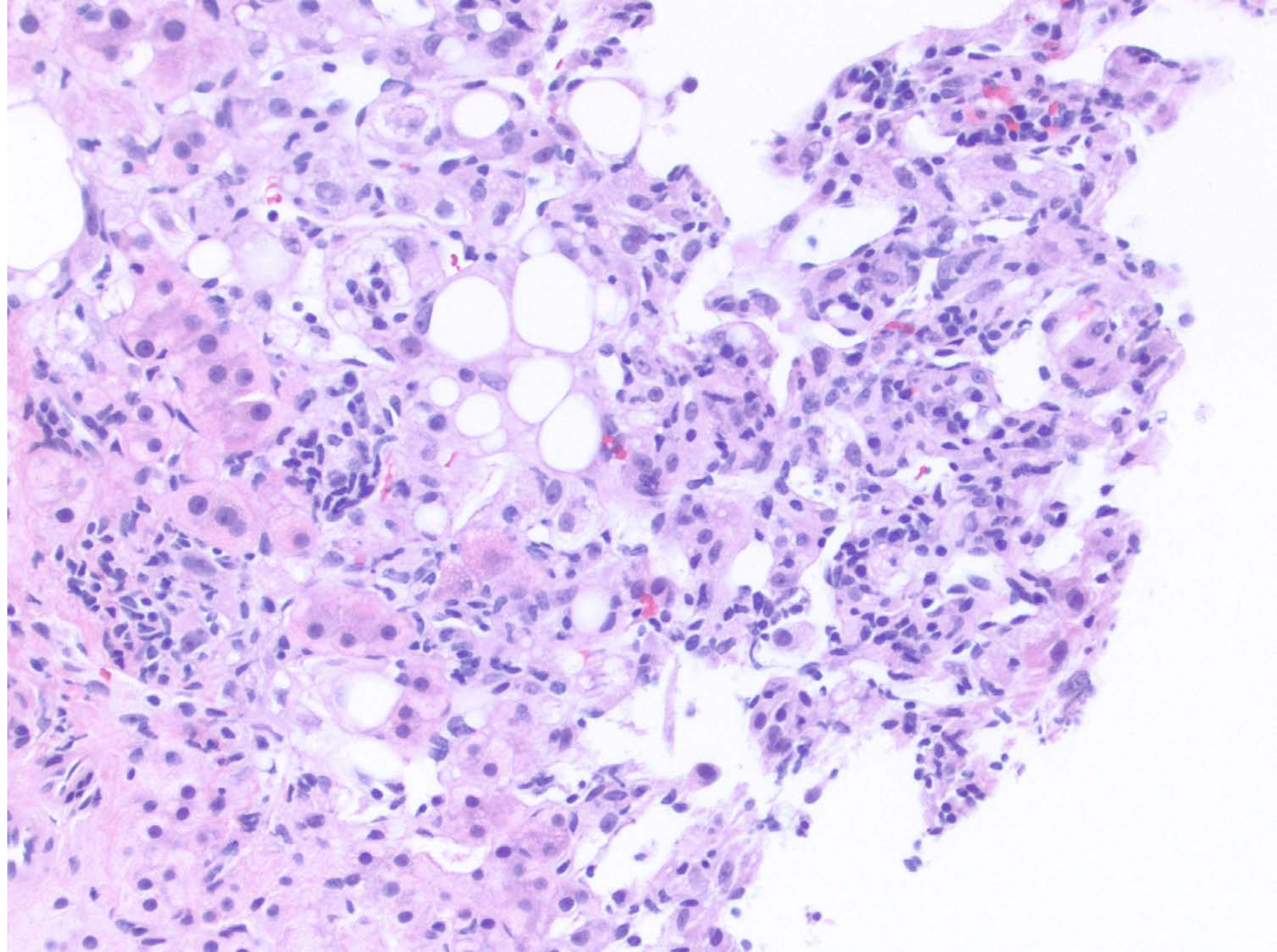
Brief History

- 37 yo F
- PMH: bicuspid aortic valve, 3 cesareans
- presented w/ R mid back pain; CT performed to r/o kidney stones/pyelonephritis; prescribed abx and pain resolved, but incidental liver mass identified.
- MRI: 6.5 cm R hepatic dome mass
- US guided biopsy was performed

10X



20X



40X

