

GUT-C

FNU SANDEEP
PGY-1
Danbury Hospital
06/04/2020

History

Clinical History:

64 year old female presents with a 2 month history of dysphagia and chronic cough. She underwent an upper GI endoscopy and screening colonoscopy (9/24/2019), followed by robotic assisted laparoscopic right colectomy (11/11/2019).

Other past medical history includes hypertension, chronic depression, multiple sclerosis.

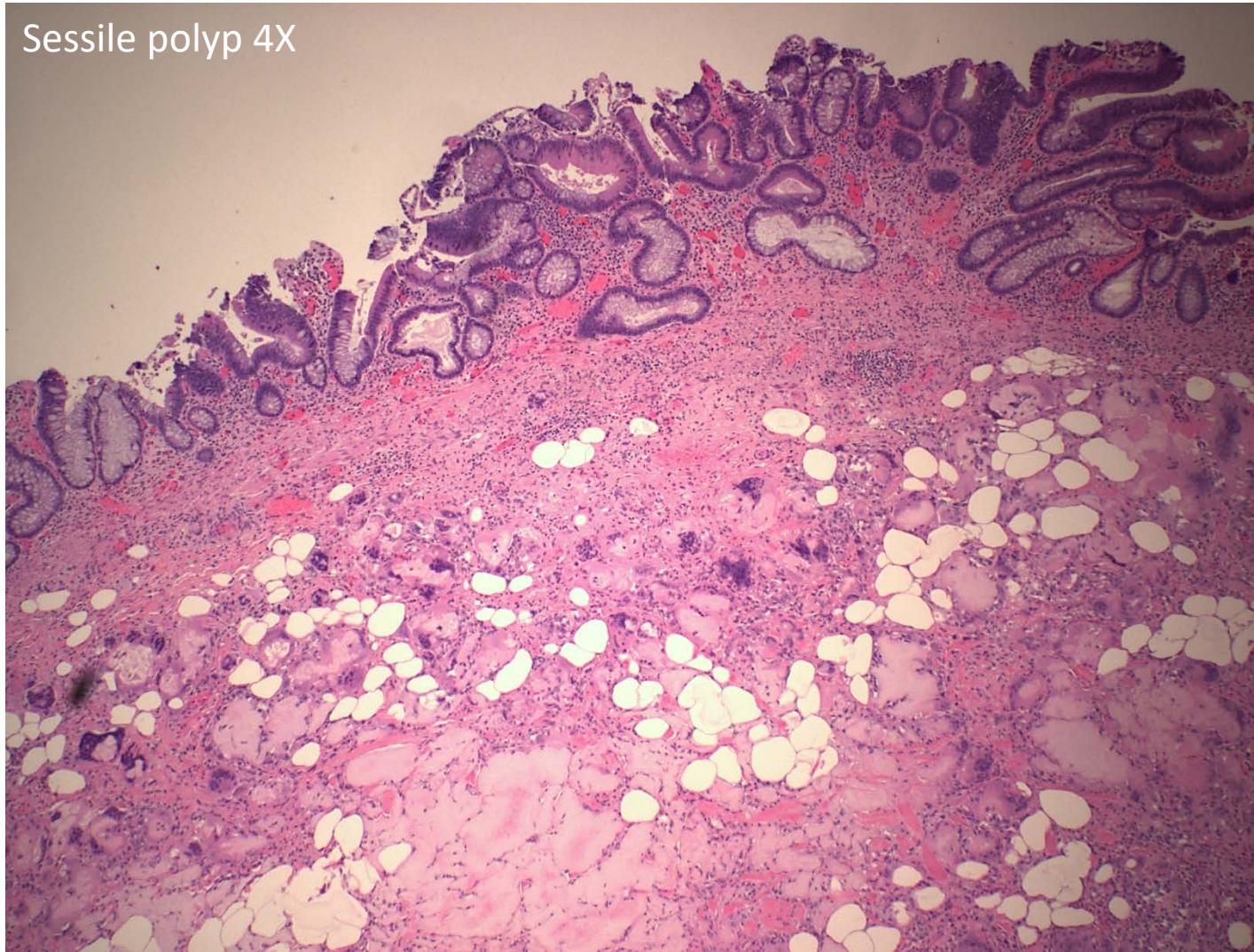
Endoscopy Findings:

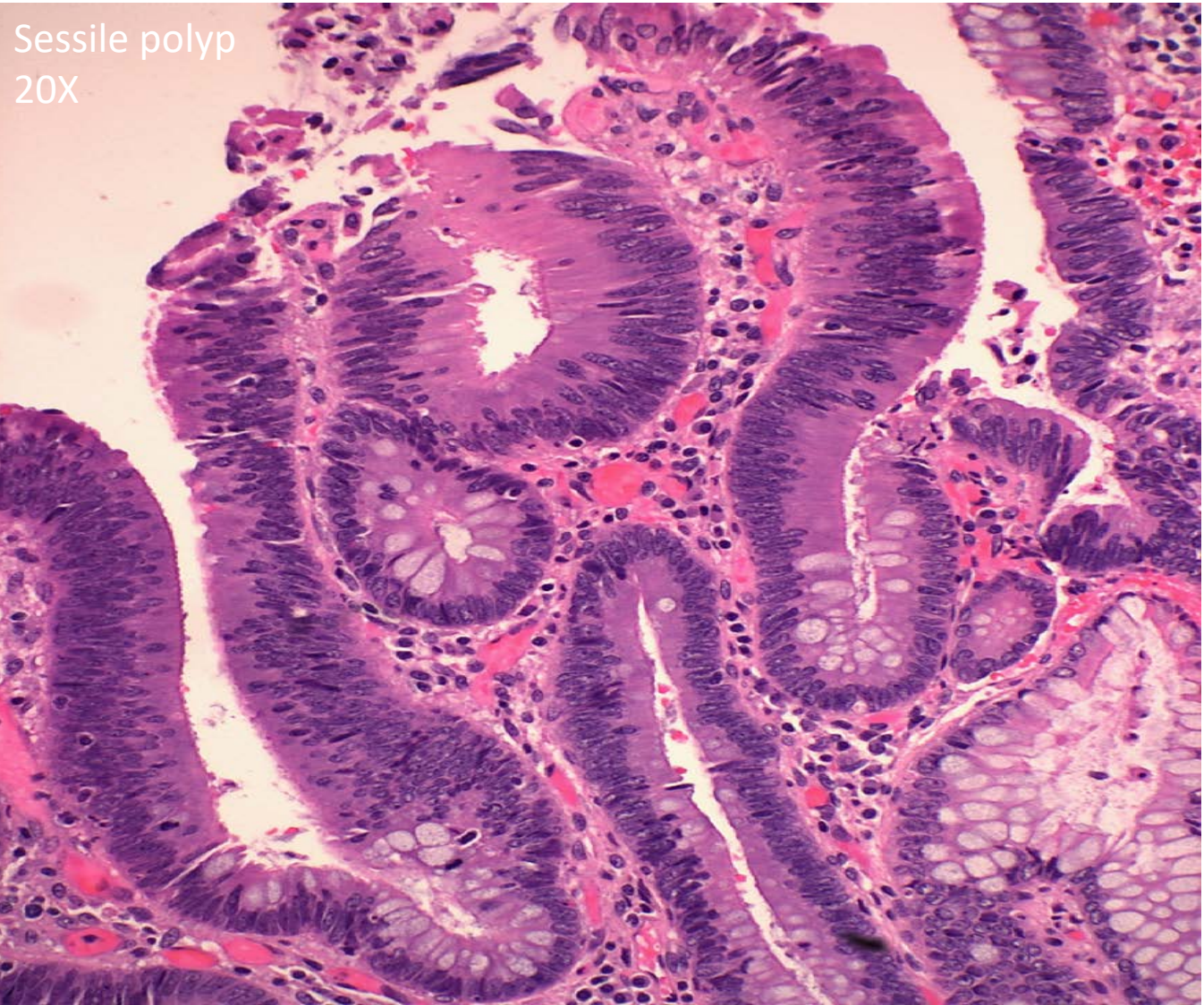
- Benign esophageal stenosis
- 20 mm cecum polyp (Polypectomy)

Gross Pathology resection specimen

Cecum: 2.6 cm sessile polyp with adjacent submucosal congestion. On sectioning mass is 0.5 cm in thickness and abuts serosal wall.

Sessile polyp 4X





Sessile polyp
20X

Sessile polyp 20X

